

## Role of Cardiovascular Magnetic Resonance as a Gatekeeper to Invasive Coronary Angiography in Patients Presenting With Heart Failure of Unknown Etiology

Ravi G. Assomull, MRCP; Carl Shakespeare, MD, FRCP; Paul R. Kalra, MA, FRCP; Guy Lloyd, MD, FRCP; Ankur Gulati, MRCP; Julian Strange, MRCP; William M. Bradlow, MD, MRCP; Jonathan Lyne, MRCP; Jennifer Keegan, PhD; Philip Poole-Wilson, FRCP, FESC; Martin R. Cowie, MD, FRCP; Dudley J. Pennell, MD, FRCP, FESC; Sanjay K. Prasad, MD, FRCP, FESC

**Background**—In patients presenting with new-onset heart failure of uncertain etiology, the role of coronary angiography (CA) is unclear. Although conventionally performed to differentiate underlying coronary artery disease from dilated cardiomyopathy, CA is associated with a risk of complications and may not detect an ischemic cause resulting from arterial recanalization or an embolic episode. In this study, we assessed the diagnostic accuracy of a cardiovascular magnetic resonance (CMR) protocol incorporating late gadolinium enhancement (LGE) and magnetic resonance CA as a noninvasive gatekeeper to CA in determining the etiology of heart failure in this subset of patients.

**Methods and Results**—One hundred twenty consecutive patients underwent CMR and CA. The etiology was ascribed by a consensus panel that used the results of the CMR scans. Similarly, a separate consensus group ascribed an underlying cause by using the results of CA. The diagnostic accuracy of both strategies was compared against a gold-standard panel that made a definitive judgment by reviewing all clinical data. The study was powered to show noninferiority between the 2 techniques. The sensitivity of 100%, specificity of 96%, and diagnostic accuracy of 97% for LGE-CMR were equivalent to CA (sensitivity, 93%; specificity, 96%; and diagnostic accuracy, 95%). As a gatekeeper to CA, LGE-CMR was also found to be a cheaper diagnostic strategy in a decision tree model when United Kingdom–based costs were assumed. The economic merits of this model would change, depending on the relative costs of LGE-CMR and CA in any specific healthcare system.

**Conclusion**—This study showed that LGE-CMR is a safe, clinically effective, and potentially economical gatekeeper to CA in patients presenting with heart failure of uncertain etiology. (*Circulation*. 2011;124:1351-1360.)

**Key Words:** cardiomyopathy ■ gadolinium ■ heart diseases ■ magnetic resonance imaging

Heart failure (HF) is a common disorder associated with a significant morbidity, mortality, and financial burden to healthcare services. The most common underlying cause is coronary artery disease (CAD), accounting for more than half of all cases, followed by nonischemic dilated cardiomyopathy (DCM).<sup>1</sup> Identification of the cause of HF is important because management of the underlying condition differs; treatment of CAD may require revascularization and secondary prevention measures such as aspirin and statins, whereas pharmacotherapy remains the mainstay of treatment in DCM. In addition, an etiology of CAD portends a worse prognosis.<sup>2</sup> Accordingly, current guidelines recommend a thorough clinical assessment including a careful history, physical exami-

nation coupled with laboratory investigations, ECG, and echocardiography to try to ascertain the underlying cause and severity of HF.<sup>3</sup> The same guidelines recommend invasive x-ray coronary angiography (CA) in any patients presenting with chest pain or significant ischemia unless the patient is not eligible for revascularization of any kind.

### Clinical Perspective on p 1360

The situation is less clear in those patients who do not present with chest pain and in whom CAD has not been excluded by means of CA. In patients with diabetes mellitus in whom ischemia may be silent or in young patients who may have coronary anomalies, CA may be justifiable. How-

Continuing medical education (CME) credit is available for this article. Go to <http://cme.ahajournals.org> to take the quiz.

Received November 30, 2010; accepted June 14, 2011.

From the Cardiovascular Magnetic Resonance Unit, Royal Brompton Hospital, London (R.G.A., C.S., A.G., J.S., W.M.B., J.L., J.K., D.J.P., S.K.P.); National Heart and Lung Institute, Imperial College London, London (R.G.A., A.G., W.M.B., J.L., J.K., P.P.-W., M.R.C., D.J.P., S.K.P.); Queen Elizabeth Hospital, Woolwich, London (C.S.); Portsmouth Hospital NHS Trust, Portsmouth (P.R.K.); and Eastbourne District General Hospital, Eastbourne (G.L.), UK.

Correspondence to Sanjay K. Prasad, MD, FRCP, FESC, Consultant Cardiologist, Cardiovascular Magnetic Resonance Unit, Royal Brompton Hospital, Sydney St, London SW3 6NP, UK. E-mail [s.prasad@rbht.nhs.uk](mailto:s.prasad@rbht.nhs.uk)

© 2011 American Heart Association, Inc.

*Circulation* is available at <http://circ.ahajournals.org>

DOI: 10.1161/CIRCULATIONAHA.110.011346

ever, in older patients with HF but no angina, there are no data to suggest that revascularization would improve clinical outcome.<sup>4</sup> Any revascularization performed would be in the hopes of improved symptoms as a result of augmented ventricular function. Although generally safe and providing hemodynamic data in addition to coronary imaging, the invasive nature of CA carries an inherent morbidity and mortality risk.<sup>5</sup> There are also issues of radiation burden, patient discomfort, and significant cost. Although angiography is often regarded as the gold standard, what is also clear now is that this investigation alone may not be sufficient to make the correct diagnosis, because several transplantation and postmortem studies have shown that CA can misdiagnose the cause of HF.<sup>6,7</sup>

We have previously demonstrated that late gadolinium-enhanced cardiovascular magnetic resonance (LGE-CMR) may have a role in excluding CAD as the underlying cause of HF. The pattern of late enhancement seen on LGE-CMR differs in patients with HF caused by DCM and CAD. A subendocardial pattern of late enhancement is seen in patients with CAD, whereas the majority of patients with DCM have either no late enhancement or a patchy midwall pattern that is not related to the territory of a coronary artery.<sup>8</sup> In addition, other groups have provided data to suggest that magnetic resonance CA (MRCA) can robustly exclude disease of the left main coronary artery or proximal 3-vessel disease with 100% sensitivity and 100% negative predictive value.<sup>9</sup> We therefore hypothesized that in patients presenting with recent-onset HF of uncertain etiology with no obvious ischemic basis, LGE-CMR was a noninvasive, safe, and cost-effective alternative to CA and could therefore act as a gatekeeper.

## Methods

### Patient Population

Patients with recently diagnosed HF (symptom onset <6 months before enrollment; n=124) were prospectively recruited between July 2004 and August 2006 from consecutive referrals at 6 HF clinics in southeast England. All patients had a diagnosis of HF with reduced left ventricular (LV) ejection fraction based on standard criteria.<sup>3,10</sup> All patients were clinically stable in New York Heart Association class I to III HF, were  $\geq 35$  years of age, and were scheduled to undergo CA as part of their clinical workup for HF. Exclusion criteria for the study included any prior history or ECG or biochemical evidence of CAD. Patients with chest pain or significant valvular disease were also not enrolled. In addition, the scanning protocol involved MRCA, so patients with atrial fibrillation were also excluded because the MRCA sequences used perform poorly in the context of a highly variable R-R interval. Finally, all patients with standard contraindications to CMR were also excluded. The recruited patients therefore had HF of uncertain origin with no clinical evidence of CAD and were in sinus rhythm.

On recruitment, patients underwent CMR with both myocardial LGE and MRCA. Patients also underwent CA as part of their standard clinical investigation. All patients were recruited before undergoing CA, and none was denied a CMR scan as a consequence of the CA findings in cases when CA was performed before LGE-CMR. The project was approved by the local institutional ethics committee. All participants gave written informed consent.

### Cardiovascular Magnetic Resonance

Cine CMR (Siemens Sonata 1.5T [n=42] and Siemens Avanto [n=78]) was performed with steady-state, free-precession breath-hold cines (echo time/repetition time, 1.6/3.2 ms; flip angle, 60°) in

long-axis planes and sequential contiguous 7-mm short-axis slices (3-mm gap) from the atrioventricular ring to the apex. The LGE images were acquired 10 minutes after intravenous gadolinium-DTPA (Schering; 0.1 mmol/kg) in identical short-axis planes using an inversion-recovery gradient echo sequence. Inversion times were adjusted to null normal myocardium (typically 320 to 440 ms; pixel size, 1.7×1.4 mm). In all patients, imaging was repeated for each short-axis image in 2 separate phase-encoding directions to exclude artifact. Late gadolinium enhancement was deemed to be present only when the area of signal enhancement could be seen in both phase-swapped images and a cross-cut long-axis image.

We performed MRCA in all patients using a free-breathing, navigator-based, fat-suppressed, balanced, steady-state free-precession sequence (echo time, 1.47 ms; repetition time, 3.5 ms). Phase ordering with automatic window selection<sup>11</sup> was implemented to maximize the respiratory efficiency. For the left main stem, left anterior descending (LAD), and left circumflex coronary arteries, a 3-dimensional volume was imaged by use of a 3-point plan-scan tool with the center of the volume focused on the left main coronary artery. Changes in the anteroposterior and left-right angulation of 5° were made to ensure maximal coverage of the proximal LAD and left circumflex coronary. The right coronary artery was similarly imaged with the aid of the 3-point plan-scan tool. Each volume consisted of eight 3-mm slices reconstructed to sixteen 1.5-mm slices. A field of view of 300×300 mm with a 320×320 matrix yielded an in-plane pixel size of 0.9×0.9 mm. A partial Fourier factor of 6/8 was implemented in the in-plane phase-encoding direction, and 25% oversampling was performed in the through-plane phase-encoding direction. Imaging was performed during the mid-diastolic rest period, the duration and onset of which were determined from viewing a 4-chamber cine acquisition.<sup>12</sup> The number of phase-encoded steps acquired per cardiac cycle was dependent on the duration of this rest period and varied from 20 to 40, resulting in an acquisition window of 70 to 140 ms and an acquisition duration ranging from 60 to 120 cardiac cycles (assuming 100% respiratory efficiency).

### Cardiovascular Magnetic Resonance Image Analysis

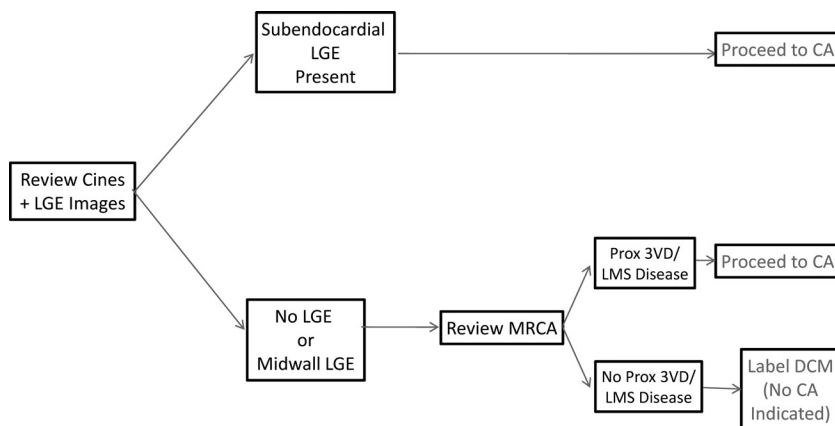
Ventricular volumes and function were measured for the LV with standard techniques<sup>13</sup> and analyzed with semiautomated software (CMRtools, Cardiovascular Imaging Solutions, London, UK). The presence of late enhancement was predefined as regions with an increase in signal intensity of >2 SD of remote normal myocardium. Coronary stenosis on MR angiography was predefined as >50% in any of the major epicardial vessels.

### Assessment of Etiology

Etiology was assessed by 3 independent consensus groups—a CMR arm, a conventional x-ray angiogram arm, and a gold-standard group—that had access to and reviewed all clinical and imaging data.

### Cardiovascular Magnetic Resonance Arm

For analysis of the CMR scans to determine the etiology of HF, a consensus group of 3 expert cardiologists reviewed the CMR scans using a predefined algorithm (Figure 1). The CMR consensus group was presented with the patient's clinical history including risk factors for CAD. They were blinded to the x-ray angiography data. All data were anonymized. The cine and LGE sequences were presented. Cine imaging was carefully analyzed for regional and global hypokinesia and correlated with late gadolinium images. If subendocardial LGE was present, the cardiologists were directed to recommend proceeding to CA with the view that there was evidence of underlying CAD resulting from evidence for prior myocardial infarction. In the absence of subendocardial LGE (ie, either no LGE or the presence of midwall LGE), the MRCA images were reviewed. If the MRCA images revealed left main stem or severe proximal 3-vessel disease, the cardiologists were also directed to recommend proceeding to CA to definitively exclude CAD as the underlying cause. In the absence of both subendocardial LGE and left main



**Figure 1.** Predefined decision algorithm for the cardiac magnetic resonance consensus panel to decide whether to proceed to invasive x-ray coronary angiography (CA). The algorithm states that the presence of subendocardial late gadolinium enhancement (LGE) should trigger the decision to proceed to CA. In cases when subendocardial LGE is not present, magnetic resonance coronary angiography (MRCA) images should be reviewed before deciding whether CA is required. The review of MRCA should exclude proximal severe 3-vessel disease (Prox 3VD) or left main stem (LMS) disease (Prox 3VD) or left main stem disease before a scan be labeled dilated cardiomyopathy (DCM).

stem/proximal 3-vessel disease on MRCA, a diagnosis of DCM was ascribed by the consensus panel with the implication that CA was not required for further evaluation of the underlying etiology.

### Conventional X-Ray Angiography Arm

A separate consensus group of 3 experienced cardiologists with expertise in coronary intervention was presented with the clinical history and the CA images (including left ventriculograms) in an anonymized format. These physicians were blinded to the CMR data, and all data were anonymized. The cardiologists were asked to independently ascribe an underlying cause for the HF using a structure based on a standardized definition of ischemic cardiomyopathy as proposed by Felker et al.<sup>14</sup> In summary, patients were ascribed an underlying etiology of CAD if there was obstructive CAD of >50% in the left main vessel or of >75% stenosis in either the proximal LAD or  $\geq 2$  epicardial coronary arteries. Single-vessel disease not involving the proximal LAD was treated as nonischemic because the extent of LV dysfunction would be considered to be out of proportion to the extent of CAD.

Standardized coronary anatomy was used to delineate the distribution of CAD.<sup>15</sup> The third consensus group member's view was required only when there was disagreement between the 2 primary group members.

### Gold-Standard Arm

A final independent and separate consensus group of 3 cardiologists reviewed all the anonymized data and ascribed a gold-standard etiology based on a review of all the clinical data, including tissue characterization information from LGE-CMR and luminographic data from CA. From the permutations of CAD and LGE pattern seen, the gold-standard group categorized causes into 1 of 6 groups as follows (see Figure 2): (1) nonischemic DCM, either no LGE or midwall LGE on CMR and unobstructed coronary arteries on CA (true DCM); (2) HF secondary to CAD, ischemic pattern of LGE that involves the subendocardium in  $\geq 3$  segments with at least 1 stenosis of >75% seen in coronary artery(ies)<sup>16</sup> subtending the affected area of infarction evident on CA (true CAD); (3) nonischemic DCM with bystander infarct, small area of subendocardial LGE affecting  $\leq 2$  of 17 segments in a globally hypokinetic LV with unobstructed coronary arteries on CA (DCM with bystander infarct); (4) nonischemic DCM with bystander CAD, either no LGE or midwall LGE with coronary stenosis(es) considered insufficient to explain the extent of LV dysfunction (DCM with bystander CAD, ie, disease not affecting the left main stem/proximal LAD or significant  $\geq 2$  vessel disease); (5) HF caused by ischemic heart disease with unobstructed coronary arteries,  $\geq 3$  segments of subendocardial/transmural LGE in a perfusion territory typical of a coronary artery with associated regional hypokinesia and unobstructed coronary arteries on CA, ie, probable recanalization, spasm, or embolic episode (myocardial infarction with unobstructed coronary arteries); and (6) HF resulting from CAD with no subendocardial LGE but severe proximal 3-vessel disease/left main stem disease on CA (severe proximal CAD on CA without infarction).

### Follow-Up of Patients

As an additional check, to corroborate the findings of the gold-standard consensus group, follow-up data were collected prospectively in all recruited patients. Patient events were recorded by communication with patients, their cardiologists, and general practitioners. Medical records were reviewed after attendance at outpatient clinics or hospitalization.

All patients were directly contacted at enrollment and at 6 monthly intervals during follow-up. No patient was lost to follow-up. The data were reviewed to determine whether there was any change in subsequent clinical diagnosis compared with the initial diagnosis ascribed by the gold-standard consensus group.

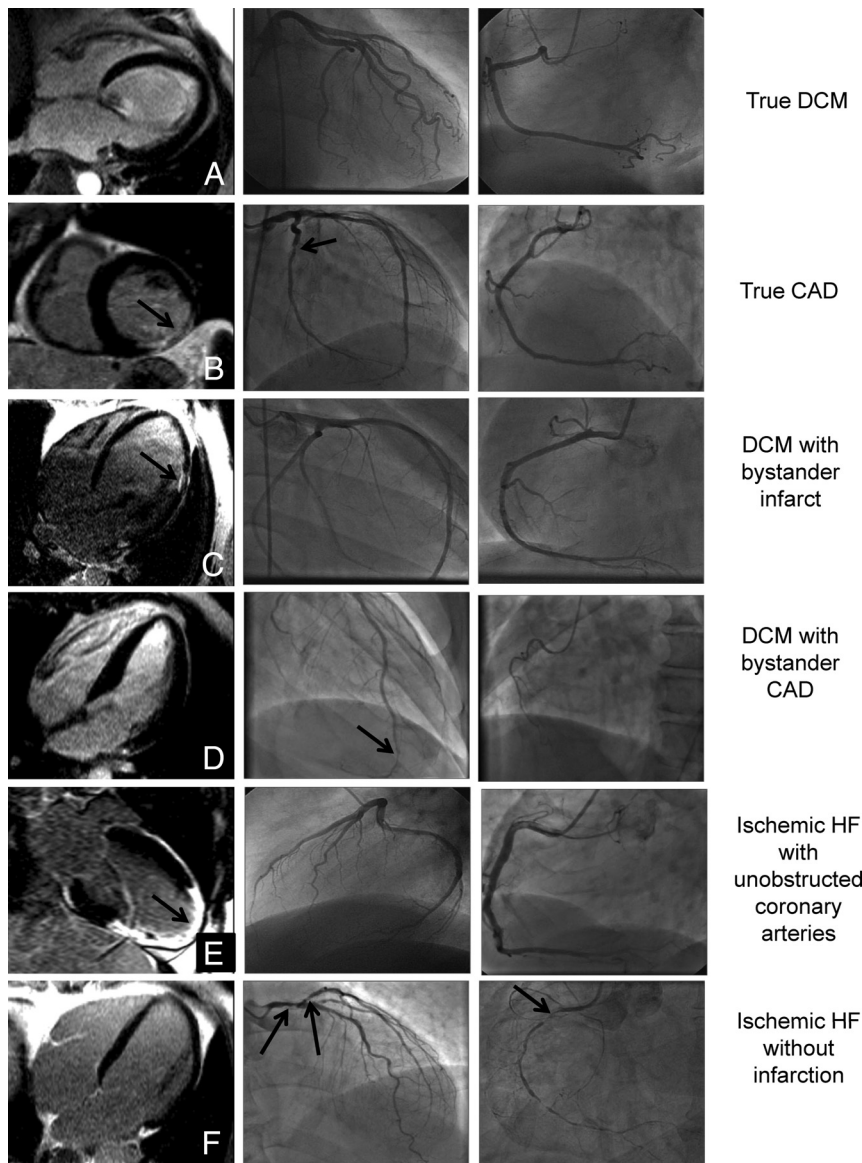
### Diagnostic Cost Comparison

A decision tree model was constructed with LGE-CMR positioned as a gatekeeper to CA (Figure 3). From the latest cost data from the 2008 to 2009 UK National Health Service (NHS) tariffs, the cost of a coronary angiogram without complications was set at £1255.<sup>17</sup> Because no national NHS tariff for CMR had yet been set at the time of this study, the cost of a CMR scan was set at £600, in line with current charges at UK NHS centers. The cost of using LGE-CMR as a gatekeeper to CA was compared with using the traditional method of only CA by implementing the above costs. The accuracy of each test was factored into the cost comparison by indexing the total cost of each strategy over the number of correct diagnoses.

### Statistical Analysis

Before enrollment, a sample size calculation was performed to power the study to demonstrate equivalence between LGE-CMR and CA in diagnosing the underlying cause of HF.<sup>18</sup> The sample size for this study was calculated assuming that x-ray CA correctly classifies the cause of HF on 90% of occasions and that this value is the same for LGE-CMR. The study was powered at 80% with an  $\alpha$  error of 0.05 to classify equivalence as a difference of <10% between the 2 diagnostic strategies. With these assumptions, 111 patients in each group were required, and the protocol aimed for recruitment of 122 patients assuming a 10% dropout rate. All patients were recruited to both LGE-CMR and CA groups. Each consensus group was blinded to either LGE-CMR or CA data as appropriate, thereby validating the inclusion of the same patients in both groups.

All continuous variables are expressed as mean  $\pm$  SD, and the distribution of categorical variables is expressed as frequencies. To evaluate the relative accuracy of LGE-CMR and CA in diagnosing the underlying cause of HF, calculations of sensitivity, specificity, and positive predictive and negative predictive values were performed, with the gold-standard consensus group diagnosis being the comparator. The costs for the 2 diagnostic strategies were compared by use of the Mann-Whitney *U* statistic, which was corrected for ties. For all statistical tests used, a value of  $P < 0.05$  was deemed to be statistically significant. Stata version 10 was used for all statistical analyses.



**Figure 2.** Late gadolinium-enhanced cardiovascular magnetic resonance (LGE-CMR) and associated coronary angiogram (CA) images of diagnosis subtypes. Six different diagnoses are graphically represented with LGE-CMR images followed by CA images of the left coronary artery and right coronary artery. **A**, True dilated cardiomyopathy (DCM) shows an LGE-CMR image with no subendocardial LGE and unobstructed coronary arteries on CA. **B**, True coronary artery disease (CAD) with a circumflex territory infarct on CMR (arrows) and a severe proximal circumflex artery stenosis (arrows). **C**, A small area of subendocardial LGE (arrows) is seen in a severely dilated left ventricle with severe global systolic impairment and unobstructed coronary arteries representing DCM with bystander infarct. **D**, Distal disease of the left anterior descending artery (arrows) with no evidence of subendocardial LGE (DCM with bystander CAD). **E**, A large apical infarct is seen on LGE-CMR in the context of unobstructed coronary arteries suggesting ischemic heart failure (HF) with unobstructed coronary arteries. **F**, A possible scenario of ischemic heart failure without infarction. There is no LGE on CMR but there is severe proximal 3-vessel disease, including left main stem disease, on CA (arrows). No patient in our study had this scenario; therefore, the images are for illustration only.

## Results

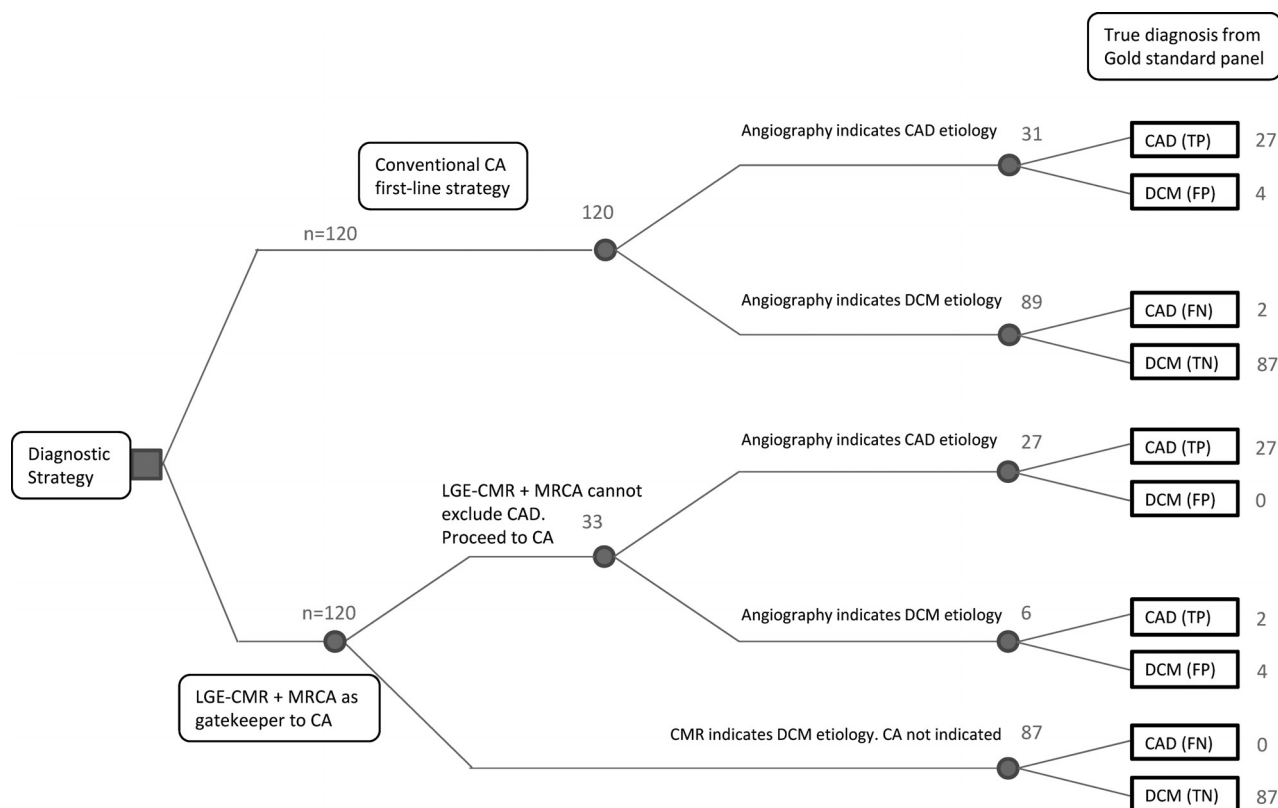
### Baseline Characteristics

The baseline characteristics of the patients are summarized in Table 1. Of the 124 patients recruited, 4 patients did not complete the study: 2 patients were unable to tolerate LGE-CMR scanning because of claustrophobia; 1 patient was found to have moderate to severe aortic regurgitation by CMR that had not been identified by echocardiography and subsequently had aortic valve surgery; and 1 patient declined CA after undergoing LGE-CMR and was therefore excluded. The final cohort therefore comprised 120 patients in whom full LGE-CMR with MRCA was carried out without complications. The same patients also underwent CA, with 2 patients suffering complications requiring hospitalization (1 femoral artery hematoma, 1 small occipital infarct periprocedurally). We performed LGE-CMR before CA in 81 of 120 patients (68%). Overall, 13 patients (11%) were admitted with acutely decompensated HF as their index presentation. These patients were treated with routine anti-HF therapy and

were recruited to the study after stabilization, with a median interval of 43 days (range, 4 to 115 days) between presentation and their CMR scan. The New York Heart Association status in Table 1 reflects the functional class at the time of the scan rather than the time of index clinical presentation. Patients had been started on conventional anti-HF therapy before undergoing their scan. In keeping with guidelines, a large proportion of patients were receiving treatment with angiotensin-converting enzyme inhibitors, angiotensin receptor blockers, and  $\beta$ -blockers.<sup>19</sup>

### Interobserver Agreement in Consensus Groups

In the CMR consensus group, the diagnosis was unanimous in a large majority of cases, and a majority decision was only required in 6 cases (5%). In the CA consensus group, the diagnosis was unanimous in a large majority of cases, and a majority decision was needed in only 3 cases (2.5%). Finally, in the gold-standard consensus group, a majority decision was needed in only 1 case.



**Figure 3.** A decision tree model summarizing the results of the decisions made by the late gadolinium-enhanced cardiovascular magnetic resonance (LGE-CMR), coronary angiography (CA), and gold-standard consensus panel groups. The model delineates the role of LGE-CMR with incorporated magnetic resonance coronary angiography (MRCA) as a gatekeeper to CA. In this model, 87 of the recruited cohort (73%) safely avoided CA and were correctly ascribed a diagnosis of dilated cardiomyopathy (DCM) by LGE-CMR. The relative diagnostic performance of using LGE-CMR against CA is represented by the true-positive (TP), false-positive (FP), true-negative (TN), and false-negative (FN) numbers presented at the end of the decision tree.

### Diagnostic Accuracy

After review of all clinical, LGE-CMR, and CA data, the gold-standard consensus group deemed that 91 of the 120 cases had an underlying nonischemic etiology and were therefore classified as DCM. The remaining 29 cases were deemed to represent HF secondary to CAD. Table 2 summarizes the breakdown of cases into subgroups as outlined in the Methods section.

The decision tree (Figure 3) presents the diagnostic findings of LGE-CMR and CA and the number of correct and incorrect diagnoses. In summary, 87 of 91 cases of DCM (96%) were correctly diagnosed by LGE-CMR. In the decision tree model, these 87 patients would theoretically be able to avoid undergoing CA, thereby avoiding its associated risks and providing a significant cost saving in the diagnostic cascade. Four patients with an eventual diagnosis of DCM were put forward for CA in view of a limited area of bystander infarct. In 4 patients, LGE-CMR showed no evidence of prior infarction, and hence CA was not indicated. However, in 2 of these cases, CA documented obstructive disease in the mid LAD, and in 2 other cases, midvessel obstructive lesions were seen in the left circumflex and right coronary arteries. All patients had severe global hypokinesia and severe LV dysfunction with no evidence of prior infarction on CMR; for this reason, the gold-standard group ascribed a diagnosis of DCM with bystander CAD.

We found that LGE-CMR correctly identified all 29 patients who were ascribed CAD as the underlying cause. In 2 of these patients, an etiology of CAD was ascribed despite unobstructed coronary arteries. This view was reached by virtue of the observation that there was a large territory of subendocardial/transmural LGE consistent with the supply of at least 1 major epicardial artery with relatively well-preserved wall thickening in other unaffected areas. There were no patients in whom LGE-CMR suggested a diagnosis of DCM and corresponding CA documented significant left main stem, proximal LAD, or 3-vessel disease. Of the patients with a diagnosis of DCM, 25 had a midwall pattern of fibrosis.

In addition, CA correctly identified 87 of 91 cases (96%) of DCM. As stated, 4 patients were incorrectly ascribed as having CAD when the gold-standard diagnosis was DCM. Coronary angiography identified all but 2 cases of HF caused by CAD.

The sensitivity, specificity, positive/negative predictive values, and overall diagnostic accuracy for both LGE-CMR and CA are presented in Table 3.

### Cost Savings of Using Late Gadolinium-Enhanced Cardiovascular Magnetic Resonance as a Gatekeeper

Assuming the costs for each investigation as stated in the Methods section and applying the results from this study, the

**Table 1. Baseline Characteristics at the Time of the Cardiac Magnetic Resonance Scan (n=120)**

Characteristic	
Age (SD), y	57 (11)
Male sex, n (%)	96 (80)
Family history of DCM, n (%)	7 (6)
Family history of CAD, n (%)	20 (17)
History of diabetes mellitus, n (%)	20 (17)
History of hypertension, n (%)	56 (47)
History of smoking, n (%)	29 (24)
History of alcohol excess, n (%)	7 (6)
Preceding flu-like illness, n (%)	11 (9)
Heart failure duration before enrollment (SD), d	63 (39)
Interval between CMR and coronary angiogram (SD), d	37 (29)
NYHA class at the time of enrollment, n (%)	
I	29 (24)
II	75 (63)
III	16 (13)
Medication, n (%)	
Aspirin	56 (47)
ACEI/ARB	110 (92)
$\beta$ -blocker	84 (70)
Spironolactone	24 (20)
Digoxin	2 (2)
Diuretics	73 (61)
Anticoagulation	11 (9)
Amiodarone	4 (3)
Statins	56 (47)
CMR dimensions and function (SD)	
LVEDVI, mL/m <sup>2</sup>	130 (48)
LVESVI, mL/m <sup>2</sup>	84 (48)
LVEF, %	39 (13)
LV mass index, g/m <sup>2</sup>	113 (37)

DCM indicates dilated cardiomyopathy; CAD, coronary artery disease; CMR, cardiovascular magnetic resonance; NYHA, New York Heart Association; ACEI, angiotensin-converting enzyme inhibitor; ARB, angiotensin 2 receptor blocker; LV, left ventricular; EDVI, end-diastolic volume index; ESVI, end-systolic volume index; and EF, ejection fraction.

cost of using the conventional approach of CA to evaluate underlying etiology would be £1255 per patient. Because CA has a diagnostic accuracy of 95%, the cost per correct diagnosis would be approximately £1321.

If LGE-CMR were used as a gatekeeper, all 120 patients would undergo LGE-CMR at a cost of £600 per scan. However, 87 patients would subsequently be spared CA, representing a net saving of approximately £655 per patient. Conversely, 33 patients would undergo both LGE-CMR and CA, thereby costing £1855 per patient. With these numbers, the net cost per patient using LGE-CMR as a gatekeeper to CA would be significantly less at £945 per patient ( $P=0.001$ ). Because LGE-CMR has a diagnostic accuracy of 97%, the cost per correct diagnosis would be approximately £974, which represents a 26% cost saving over using CA alone.

**Table 2. Gold-Standard Consensus Panel Categorization List**

Diagnosis	n (%)
DCM: true DCM	83 (69)
CAD: true CAD	27 (23)
DCM: bystander infarct	4 (3)
DCM: bystander CAD	4 (3)
CAD: MI with unobstructed coronary arteries on CA	2 (2)
CAD: severe proximal CAD on CA with no infarction	0 (0)

DCM indicates dilated cardiomyopathy; CAD, coronary artery disease; MI, myocardial infarction; and CA, invasive x-ray coronary angiography. Final categorization of the etiology of heart failure as ascribed by the gold-standard consensus panel.

### Clinical Follow-Up of Recruited Patients

Follow-up data were obtained for all 120 recruited patients with a mean follow-up of  $44.3 \pm 11.5$  months. In the 87 patients in whom DCM was diagnosed on the basis of unobstructed coronary arteries and no subendocardial late enhancement on CMR (true DCM), the diagnosis did not change during the follow-up period. In addition, the diagnosis in the 27 patients with LV dysfunction secondary to CAD as identified by both subendocardial scarring on CMR and significant coronary stenoses on CA (true CAD) did not change during follow-up.

In 10 cases, the findings of LGE-CMR and CA were at odds, and the eventual "correct" diagnosis was formed by the gold-standard consensus group after a review of all the clinical data. In the 4 patients with DCM with bystander CAD, only 1 patient underwent urgent revascularization 2 years after enrollment following an admission with non-ST-segment-elevation myocardial infarction. This patient was not revascularized after the initial angiography because the clinician felt the diagnosis to be DCM. In the other 3 instances, the patients had not presented subsequently with typical ischemic symptoms, and their respective clinicians had treated the patients as having DCM with pharmacotherapy and device therapy as appropriate.

In the 4 patients with DCM and bystander infarction, the clinicians continued treatment with a working diagnosis of DCM. Two of these patients also received a statin. Finally, in 2 patients in whom the diagnosis was prior myocardial infarction with unobstructed coronary arteries, both patients

**Table 3. Diagnostic Accuracy of Late Gadolinium-Enhanced Cardiovascular Magnetic Resonance and Coronary Angiography**

	LGE-CMR (95% Confidence Interval), %	CA (95% Confidence Interval), %
Sensitivity	100 (88–100)	93 (77–99)
Specificity	96 (89–99)	96 (89–99)
PPV	88 (72–97)	87 (70–96)
NPV	100 (96–100)	98 (92–100)
Diagnostic accuracy	97	95

Shown are the sensitivity, specificity, positive predictive value (PPV), negative predictive value (NPV), and diagnostic accuracy of late gadolinium-enhanced cardiovascular magnetic resonance (LGE-CMR) and invasive x-ray coronary angiography (CA) vs the gold-standard consensus group diagnosis (columns 2 and 3).

were treated with anti-HF therapy, as well as aspirin and a statin. One of these patients received an implantable converter-defibrillator because he had subsequently presented with sustained ventricular tachycardia.

### Discussion

The main finding of this study is that LGE-CMR appears to be highly effective in detecting the basis of cardiac dysfunction in patients with newly diagnosed HF in whom the etiology is unclear. It is clinically effective and economically viable as a gatekeeper to CA.

Specifically, these patients had neither prior history of ischemic heart disease nor any chest pain that may represent underlying CAD. Current guidelines for the management of HF state that there is little evidence for benefit from revascularization in these groups but offer no firm guidance on a noninvasive alternative. This is also particularly important because nearly half of patients with HF and low ejection fraction have normal or near-normal coronary arteries on angiography with an underlying myocardial disorder responsible for the clinical presentation. At present, this is not fully characterized unless an endomyocardial biopsy is performed.

Identification of the condition responsible for the cardiac structural and/or functional abnormalities may be important because some conditions that lead to LV dysfunction are potentially treatable and/or reversible.<sup>3</sup> Conventional imaging often has a low yield in detecting the underlying cause, and as a consequence, present guidelines do not advocate routine angiography. However, this is at odds with the practice of many healthcare providers and autopsy data on the underlying etiology. A major strength of CMR is its ability to provide tissue characterization *in vivo*, yielding information on the underlying cause and risk stratification plus guiding device implantation.<sup>19–21</sup> Importantly, this information is incremental to coronary anatomy findings alone. There is therefore an opportunity to reappraise the role of noninvasive imaging in identifying the underlying cause and management plan in this cohort of patients.

### Clinical Implications

The cohort studied was representative of those normally encountered in an HF service. Most were in at least New York Heart Association class III at the time of their original index presentation. They had been stabilized on anti-HF therapy reflected by an improvement in functional status by the time of recruitment; the clinical challenge was to elucidate the underlying cause.

Our data demonstrate that LGE-CMR shows diagnostic equivalence to CA in revealing the underlying etiology of this poorly studied cohort. In addition, the positioning of LGE-CMR as a gatekeeper to CA allows the safe avoidance of CA in  $\approx 75\%$  of this cohort who had DCM. This represents an opportunity for a significant cost saving in the management of these patients in a noninvasive manner with no ionizing radiation exposure or need for inpatient stay. Another advantage is that, with a single test, data are provided on biventricular function, tissue characterization, viability, and risk stratification.<sup>19</sup>

Two prior studies have quoted modest success in comparing LGE-CMR with CA in this type of cohort but without additional MRCA to exclude severe proximal disease.<sup>16,22</sup> Both of these studies suggest an overall sensitivity of 81% to 86% with a specificity of 91% to 93% in determining the presence of obstructive CAD. However, the authors acknowledged that the presence of obstructive CAD did not in itself represent an underlying cause of ischemia-driven HF because of coincidental and noncontributory CAD. Indeed, in our study, defining the gold standard for diagnosis of CAD as the contributory reason for HF as a 70% lesion in at least 1 vessel would produce sensitivity/specificity numbers similar to those obtained by Soriano et al.<sup>16</sup> Another study<sup>23</sup> addresses this flaw to a certain extent by using a validated definition for ischemic cardiomyopathy that allows the presence of single-vessel disease without a history of myocardial infarction to represent nonischemic HF.<sup>14</sup> Both studies also did not have any mechanism in their CMR protocol to detect the uncommon but important group of patients in whom CAD may contribute to HF by virtue of severe proximal 3-vessel disease without prior infarction. The use of MRCA in our study design addresses this potential pitfall. Our study used the refined, validated, and more realistic definition for ischemic cardiomyopathy that precludes the scenario of a single lesion in either the circumflex or right coronary artery being deemed sufficient to cause global hypokinesia with resultant severe LV dysfunction. The present study is unique in being the first that is adequately powered to assess the diagnostic accuracy of LGE-CMR at baseline as a gatekeeper to CA compared with a robust gold standard. Most important, its findings are also validated against prospective clinical follow-up.

The gold-standard consensus group with access to a full data set of CMR-based tissue characterization and coronary disease burden from CA was best equipped to provide the most accurate cause of HF. The reason is that this group was afforded the opportunity to integrate the severity of coronary disease with the extent of prior infarction and to consider whether the location and severity of any documented CAD would be adequate to cause ischemic myocardial hibernation. This study also advocates a more rigorous classification of the underlying cause in patients with HF based on a combination of luminal angiography and myocardial tissue characterization. These have been broadly classified into 6 subsets from the findings of the gold-standard group, challenging the traditional dichotomy of ischemic and nonischemic cardiomyopathy.

Other smaller studies have been performed to assess LGE-CMR in a similar role with respect to the management of HF.<sup>24,25</sup> However, these studies included patients with chest pain or clinical features of CAD; therefore, a comparison with our study is not strictly valid. Pilz et al<sup>26</sup> have also used a “gatekeeper” model to argue for a role for adenosine stress CMR in a different cohort of patients with a class II indication for CA. Their data show that the rates of CA in this cohort who have an intermediate probability of CAD could be reduced by  $>80\%$ . In our protocol, the use of first-pass perfusion was considered but was decided against because nuclear studies have demonstrated that perfusion defects may be present in nonischemic cardiomyopathies.<sup>27,28</sup> The use of first-

pass perfusion would therefore not necessarily help discriminate an underlying ischemic from nonischemic etiology.

Computed tomography CA represents a noninvasive alternative to conventional CA.<sup>29</sup> However, it has a significant radiation burden and currently is not used to provide tissue characterization data at acceptable levels of radiation exposure. It is therefore subject to the same diagnostic pitfalls as conventional CA.<sup>30,31</sup> There has also been interest in the role of stress and contrast echocardiography in a similar cohort.<sup>32</sup> This has the advantage of portability, and although it provides important information on function and ischemia, it lacks detailed tissue characterization and hence cannot delineate different patterns of fibrosis. Interpretation is also more operator dependent. Nuclear techniques have the advantage of long-term outcome data but also do not reliably distinguish patterns of fibrosis characteristic of the underlying etiology and carry a significant radiation burden. Increasingly, the presence of fibrosis per se has been shown to be of important prognostic significance, and this information is not obtained by these alternative techniques.

### Limitations

We performed LGE-CMR within  $37 \pm 29$  days of CA. Although short, this period represents a potential opportunity for a clinical event between the 2 procedures being performed. However, none of the patients had evidence of new cardiac events, required hospitalization, or had any form of therapy changed between their respective LGE-CMR and CA. The gold-standard diagnosis was provided by highly experienced cardiologists who were familiar with the performance and interpretation of CA and LGE-CMR. However, the consensus view that they provided was effectively an opinion. This is potentially contentious in the group of patients who represent a “gray area” in which LGE-CMR and CA provided potentially contradictory conclusions. However, validation of their opinion in all of these gray cases was provided by 3.5-year follow-up data, which showed that all the diagnoses ascribed by the consensus group were mirrored by the patients’ own physicians and clinical outcomes. In addition, the diagnosis changed in only 1 patient with features of DCM on LGE-CMR and single-vessel CAD; 2 years after enrollment, he represented with an acute coronary syndrome, which represented a new and unrelated event. Repeat CA in this patient demonstrated a clear progression of CAD, which warranted revascularization with PCI. None of the patients with bystander CAD required or underwent revascularization to evaluate any subsequent improvement in LV function. In addition, as a result of improving clinical status, none of the patients required or underwent myocardial biopsy. In patients with a predominant DCM phenotype but with concurrent CAD, angiography potentially provides useful information that could be missed by CMR alone. However, recent trials indicate that this is unlikely to affect outcomes in this cohort. Most notably in the Controlled Rosuvastatin Multinational Trial in Heart Failure (CORONA),<sup>33</sup> statins had no significant benefit in patients with HF, regardless of etiology. Reflecting this, there was no adverse outcome overall based on their management plan.

At times, the findings in this subgroup of gray cases may be difficult to synthesize. They present a diagnostic and

management dilemma for clinicians; therefore, further work is needed to uncover the prognosis in this group compared with patients with true DCM (no CAD on CA and no subendocardial LGE on CMR). However, LGE-CMR appears to provide some assistance in reaching the right clinical decision in this underrecognized group.

The MRCA sequence required a regular ECG to obtain images of adequate spatial resolution. For this reason, patients with atrial fibrillation were excluded. We also excluded all patients with chest pain even though this symptom may be present in HF of either type. It was felt that any patients with symptoms suggesting possible angina ought to have CA to ensure that they were not denied the chance of revascularization as a therapeutic option.

Computed tomography CA may have provided higher sensitivities and specificities in the exclusion of CAD but with an increased radiation burden along with the risks associated with iodine-based contrast agents. Detailed tissue characterization is also not currently possible with computed tomography. We included MRCA in our protocol to ensure that we did not miss patients with severe proximal coronary disease but no infarction. However, no such patients were encountered, suggesting that this is an important but uncommon presentation.<sup>24</sup>

It should also be noted that the cohort we studied consisted predominantly of patients with mild to moderate HF in sinus rhythm and no symptoms consistent with myocardial ischemia, and results may not apply to patients with more severe or advanced HF. This is also relevant to MRCA, which may have a different and potentially lower negative predictive value in a broader cohort of HF patients when there is a higher burden of CAD.

Finally, the potential cost savings of this procedure will depend on local/national relative reimbursement rates for both CMR and CA. Hence, these data are most applicable to healthcare services in which CMR is less expensive than CA.

### Conclusions

Cardiovascular magnetic resonance is a safe, clinically effective, and fiscally prudent gatekeeper to CA in patients presenting with new-onset HF with no features of chest pain or prior myocardial infarction. It is of particular value in clarifying the underlying pathophysiology in patients who are likely to have dual pathology by establishing the dominant cause. Additional information is provided on biventricular assessment, tissue characterization, risk stratification, and likelihood to benefit from device therapy. Unique aspects of our study compared with previous work are the comparison of findings with a gold-standard panel including CMR and angiography rather than CA alone and corroboration of these findings through subsequent clinical follow-up. Our study also suggests the need for a paradigm shift from a simple classification of ischemic versus nonischemic etiology in this cohort based on luminography to one that refines the Felker et al<sup>14</sup> criteria incorporating myocardial tissue characterization. Further studies are required to identify the prognosis in this cohort with particular focus on the subgroup of gray cases in whom there appears to be concurrent CAD with nonischemic DCM.



## Acknowledgments

Dr Poole-Wilson died before submission of this article. We would like to dedicate this article to the enthusiasm and inspiration he provided.

## Sources of Funding

This study was supported by the UK NIHR Cardiovascular Biomedical Research Unit at Royal Brompton and Harefield NHS Foundation Trust and Imperial College London. Dr Assomull received a British Heart Foundation Grant. This study was also supported by CODA UK.

## Disclosures

Dr Pennell is a consultant to Siemens and a director of Cardiovascular Imaging Solutions Ltd. Dr Cowie has consultancy agreements with Pfizer, Takeda, and Servier. The other authors report no conflicts.

## References

1. Fox KF, Cowie MR, Wood DA, Coats AJ, Gibbs JS, Underwood SR, Turner RM, Poole-Wilson PA, Davies SW, Sutton GC. Coronary artery disease as the cause of incident heart failure in the population. *Eur Heart J*. 2001;22:228–236.
2. Bart BA, Shaw LK, McCants CB Jr, Fortin DF, Lee KL, Califf RM, O'Connor CM. Clinical determinants of mortality in patients with angiographically diagnosed ischemic or nonischemic cardiomyopathy. *J Am Coll Cardiol*. 1997;30:1002–1008.
3. Hunt SA, Abraham WT, Chin MH, Feldman AM, Francis GS, Ganiats TG, Jessup M, Konstam MA, Mancini DM, Michl K, Oates JA, Rahko PS, Silver MA, Stevenson LW, Yancy CW. 2009 Focused update incorporated into the ACC/AHA 2005 guidelines for the diagnosis and management of heart failure in adults: a report of the American College of Cardiology Foundation/American Heart Association Task Force on Practice Guidelines: developed in collaboration with the International Society for Heart and Lung Transplantation. *Circulation*. 2009;119:e391–e479.
4. Eagle KA, Guyton RA, Davidoff R, Edwards FH, Ewy GA, Gardner TJ, Hart JC, Herrmann HC, Hillis LD, Hutter AM Jr, Lytle BW, Marlow RA, Nugent WC, Orszulak TA. ACC/AHA 2004 guideline update for coronary artery bypass graft surgery: a report of the American College of Cardiology/American Heart Association Task Force on Practice Guidelines (Committee to Update the 1999 Guidelines for Coronary Artery Bypass Graft Surgery). *Circulation*. 2004;110:e340–e437.
5. de Bono D. Complications of diagnostic cardiac catheterisation: results from 34,041 patients in the United Kingdom confidential enquiry into cardiac catheter complications: the Joint Audit Committee of the British Cardiac Society and Royal College of Physicians of London. *Br Heart J*. 1993;70:297–300.
6. Waller TA, Hiser WL, Capehart JE, Roberts WC. Comparison of clinical and morphologic cardiac findings in patients having cardiac transplantation for ischemic cardiomyopathy, idiopathic dilated cardiomyopathy, and dilated hypertrophic cardiomyopathy. *Am J Cardiol*. 1998;81:884–894.
7. Uretsky BF, Thygesen K, Armstrong PW, Cleland JG, Horowitz JD, Massie BM, Packer M, Poole-Wilson PA, Ryden L. Acute coronary findings at autopsy in heart failure patients with sudden death: results from the Assessment of Treatment With Lisinopril and Survival (ATLAS) trial. *Circulation*. 2000;102:611–616.
8. McCrohon JA, Moon JC, Prasad SK, McKenna WJ, Lorenz CH, Coats AJ, Pennell DJ. Differentiation of heart failure related to dilated cardiomyopathy and coronary artery disease using gadolinium-enhanced cardiovascular magnetic resonance. *Circulation*. 2003;108:54–59.
9. Kim WY, Danias PG, Stuber M, Flamm SD, Plein S, Nagel E, Langerak SE, Weber OM, Pedersen EM, Schmidt M, Botnar RM, Manning WJ. Coronary magnetic resonance angiography for the detection of coronary stenoses. *N Engl J Med*. 2001;345:1863–1869.
10. *Chronic Heart Failure: Management of Chronic Heart Failure in Adults in Primary and Secondary Care: Clinical Guideline 5*. London, UK: National Institute for Clinical Excellence; 2003.
11. Jhooti P, Gatehouse PD, Keegan J, Bunce NH, Taylor AM, Firmin DN. Phase ordering with automatic window selection (PAWS): a novel motion-resistant technique for 3D coronary imaging. *Magn Reson Med*. 2000;43:470–480.
12. Plein S, Jones TR, Ridgway JP, Sivanathan MU. Three-dimensional coronary MR angiography performed with subject-specific cardiac acquisition windows and motion-adapted respiratory gating. *AJR Am J Roentgenol*. 2003;180:505–512.
13. Grothues F, Smith GC, Moon JC, Bellenger NG, Collins P, Klein HU, Pennell DJ. Comparison of interstudy reproducibility of cardiovascular magnetic resonance with two-dimensional echocardiography in normal subjects and in patients with heart failure or left ventricular hypertrophy. *Am J Cardiol*. 2002;90:29–34.
14. Felker GM, Shaw LK, O'Connor CM. A standardized definition of ischemic cardiomyopathy for use in clinical research. *J Am Coll Cardiol*. 2002;39:210–218.
15. Scanlon PJ, Faxon DP, Audet AM, Carabello B, Dehmer GJ, Eagle KA, Legako RD, Leon DF, Murray JA, Nissen SE, Pepine CJ, Watson RM, Ritchie JL, Gibbons RJ, Cheitlin MD, Gardner TJ, Garson A Jr, Russell RO Jr, Ryan TJ, Smith SC Jr. ACC/AHA guidelines for coronary angiography: executive summary and recommendations: a report of the American College of Cardiology/American Heart Association Task Force on Practice Guidelines (Committee on Coronary Angiography) developed in collaboration with the Society for Cardiac Angiography and Interventions. *Circulation*. 1999;99:2345–2357.
16. Soriano CJ, Ridocci F, Estornell J, Jimenez J, Martinez V, De Velasco JA. Noninvasive diagnosis of coronary artery disease in patients with heart failure and systolic dysfunction of uncertain etiology, using late gadolinium-enhanced cardiovascular magnetic resonance. *J Am Coll Cardiol*. 2005;45:743–748.
17. Payment by results: guidance and tariff for 2008–09. 2007. [http://www.dh.gov.uk/en/Publicationsandstatistics/Publications/PublicationsPolicyAndGuidance/DH\\_081096](http://www.dh.gov.uk/en/Publicationsandstatistics/Publications/PublicationsPolicyAndGuidance/DH_081096).
18. Blackwelder WC. "Proving the null hypothesis" in clinical trials. *Control Clin Trials*. 1982;3:345–353.
19. Assomull RG, Prasad SK, Lyne J, Smith G, Burman ED, Khan M, Sheppard MN, Poole-Wilson PA, Pennell DJ. Cardiovascular magnetic resonance, fibrosis, and prognosis in dilated cardiomyopathy. *J Am Coll Cardiol*. 2006;48:1977–1985.
20. Assomull RG, Pennell DJ, Prasad SK. Cardiovascular magnetic resonance in the evaluation of heart failure. *Heart*. 2007;93:985–992.
21. Wu KC, Weiss RG, Thiemann DR, Kitagawa K, Schmidt A, Dalal D, Lai S, Bluemke DA, Gerstenblith G, Marban E, Tomaselli GF, Lima JA. Late gadolinium enhancement by cardiovascular magnetic resonance heralds an adverse prognosis in nonischemic cardiomyopathy. *J Am Coll Cardiol*. 2008;51:2414–2421.
22. Valle-Munoz A, Estornell-Erill J, Soriano-Navarro CJ, Nadal-Barange M, Martinez-Alzamora N, Pomar-Domingo F, Corbi-Pascual M, Paya-Serrano R, Ridocci-Soriano F. Late gadolinium enhancement-cardiovascular magnetic resonance identifies coronary artery disease as the aetiology of left ventricular dysfunction in acute new-onset congestive heart failure. *Eur J Echocardiogr*. 2009;10:968–974.
23. Soriano CJ, Ridocci F, Estornell J, Perez-Bosca JL, Pomar F, Trigo A, Planas A, Nadal M, Jacas V, Martinez V, Paya R. Late gadolinium-enhanced cardiovascular magnetic resonance identifies patients with standardized definition of ischemic cardiomyopathy: a single centre experience. *Int J Cardiol*. 2007;116:167–173.
24. Casolo G, Minneci S, Manta R, Sulla A, Del Meglio J, Rega L, Gensini G. Identification of the ischemic etiology of heart failure by cardiovascular magnetic resonance imaging: diagnostic accuracy of late gadolinium enhancement. *Am Heart J*. 2006;151:101–108.
25. Schietinger BJ, Voros S, Isbell DC, Meyer CH, Christopher JM, Kramer CM. Can late gadolinium enhancement by cardiovascular magnetic resonance identify coronary artery disease as the etiology of new onset congestive heart failure? *Int J Cardiovasc Imaging*. 2007;23:595–602.
26. Pilz G, Bernhardt P, Klos M, Ali E, Wild M, Hofling B. Clinical implication of adenosine-stress cardiac magnetic resonance imaging as potential gatekeeper prior to invasive examination in patients with AHA/ACC Class II indication for coronary angiography. *Clin Res Cardiol*. 2006;95:531–538.
27. Fang W, Zhang J, He ZX. Myocardial ischemia in patients with dilated cardiomyopathy. *Nucl Med Commun*. 2010;31:981–984.
28. Sobajima M, Nozawa T, Suzuki T, Ohori T, Shida T, Matsuki A, Inoue H. Impact of myocardial perfusion abnormality on prognosis in patients with non-ischemic dilated cardiomyopathy. *J Cardiol*. 2010;56:280–286.
29. Andreini D, Pontone G, Pepi M, Ballerini G, Bartorelli AL, Magini A, Quaglia C, Nobili E, Agostoni P. Diagnostic accuracy of multidetector

- computed tomography coronary angiography in patients with dilated cardiomyopathy. *J Am Coll Cardiol*. 2007;49:2044–2050.
30. Samo G, Decraemer I, Vanhoenacker PK, De Bruyne B, Hamilos M, Cuisset T, Wyffels E, Bartunek J, Heyndrickx GR, Wijns W. On the inappropriateness of noninvasive multidetector computed tomography coronary angiography to trigger coronary revascularization: a comparison with invasive angiography. *J Am Coll Cardiol Cardiovasc Interv*. 2009;2:550–557.
31. Berman DS, Min JK. Can coronary computed tomographic angiography trigger coronary revascularization? Questioning the appropriateness of the question. *J Am Coll Cardiol Cardiovasc Interv*. 2009;2:558–560.
32. Senior R, Janardhanan R, Jeetley P, Burden L. Myocardial contrast echocardiography for distinguishing ischemic from nonischemic first-onset acute heart failure: insights into the mechanism of acute heart failure. *Circulation*. 2005;112:1587–1593.
33. Kjekshus J, Apetrei E, Barrios V, Bohm M, Cleland JG, Cornel JH, Dunselman P, Fonseca C, Goudev A, Grande P, Gullestad L, Hjalmarsen A, Hradec J, Janosi A, Kamensky G, Komajda M, Korewicki J, Kuusi T, Mach F, Mareev V, McMurray JJ, Ranjith N, Schaufelberger M, Vanhaecke J, van Veldhuisen DJ, Waagstein F, Wedel H, Wikstrand J. Rosuvastatin in older patients with systolic heart failure. *N Engl J Med*. 2007;357:2248–2261.

### CLINICAL PERSPECTIVE

Identifying the underlying etiology in patients with new onset heart failure and no overt features of underlying coronary artery disease, eg angina, can be challenging. Invasive coronary angiography (CA) carries tangible risks and does not provide tissue characterization. In this prospective study of 120 patients (powered to display non-inferiority), late gadolinium enhanced cardiovascular magnetic resonance (LGE-CMR) showed equivalence to CA when determined against a gold standard consensus panel who considered data from all the investigations. Diagnoses ascribed by LGE-CMR and CA were also validated against clinical outcomes at a median of 3.7 years. LGE-CMR is ideally placed as a gatekeeper to CA because it is safer, uniquely provides biventricular function and tissue characterization data, and is economically viable. LGE-CMR and CA were equivalent in diagnostic accuracy (97% versus 95%) and the data suggests that 73% of patients would have appropriately avoided CA, being spared the risks and costs of this investigation. Importantly, no patient with prognostically important coronary artery disease would have been denied CA and any subsequent revascularization as LGE-CMR had a negative predictive value of 100%. The data also suggests the need for a paradigm shift in the classification of patients with heart failure to reflect not just coronary anatomy, but also myocardial tissue characterization. This study therefore challenges the traditional dichotomy of ischemic versus nonischemic cardiomyopathy by revealing subgroups of patients with features of both ischemic and nonischemic etiologies.

Go to <http://cme.ahajournals.org> to take the CME quiz for this article.

## **Role of Cardiovascular Magnetic Resonance as a Gatekeeper to Invasive Coronary Angiography in Patients Presenting With Heart Failure of Unknown Etiology**

Ravi G. Assomull, Carl Shakespeare, Paul R. Kalra, Guy Lloyd, Ankur Gulati, Julian Strange, William M. Bradlow, Jonathan Lyne, Jennifer Keegan, Philip Poole-Wilson, Martin R. Cowie, Dudley J. Pennell and Sanjay K. Prasad

*Circulation*. 2011;124:1351-1360; originally published online September 6, 2011;  
doi: 10.1161/CIRCULATIONAHA.110.011346

*Circulation* is published by the American Heart Association, 7272 Greenville Avenue, Dallas, TX 75231  
Copyright © 2011 American Heart Association, Inc. All rights reserved.  
Print ISSN: 0009-7322. Online ISSN: 1524-4539

The online version of this article, along with updated information and services, is located on the  
World Wide Web at:

<http://circ.ahajournals.org/content/124/12/1351>

**Permissions:** Requests for permissions to reproduce figures, tables, or portions of articles originally published in *Circulation* can be obtained via RightsLink, a service of the Copyright Clearance Center, not the Editorial Office. Once the online version of the published article for which permission is being requested is located, click Request Permissions in the middle column of the Web page under Services. Further information about this process is available in the [Permissions and Rights Question and Answer](#) document.

**Reprints:** Information about reprints can be found online at:  
<http://www.lww.com/reprints>

**Subscriptions:** Information about subscribing to *Circulation* is online at:  
<http://circ.ahajournals.org/subscriptions/>